

Narrow jaw implants: innovation improves quality of life

author_ Dr Klaus Müller/Germany

Since the initial publication of reports describing the success of implant treatment (Pruin and Heinrich), edentulous lower and upper jaw conditions (implant indication class III) have been associated with the treatment concept of bar splinting and immediate loading. All the technical solutions for manufacturing accurately-fitting bars (Sheffield Test) on the basis of spark erosion, electroplating or prefabricated auxiliary parts are considered to be sound.



Fig. 5

Fig. 1–3 Usual simple preparation of the implant bed taking into account the necessary prosthetic axes.

Fig. 4 Intraoperative impression taking using the pick up technique. Impression posts can also be used at the same time as bar sleeves.

Fig. 5 Non-precious metal round bar is shortened to the required length and prepared for soldering or laser welding.

_Increased susceptibility to plaque because of diminishing motivation or failure to care for the teeth adequately due to age or illness impairs dental health. The use of one- or two-part implant systems with a macroporous surface up to the implant neck often led to inflammation and a gradual loss of osseointegration, bringing discredit on a treatment that was quick to carry out. However, the primary splinting protected the implants for a long period from non-axial stress and loosening if the superstructure was fractured or if relining on recall was inadequately carried out. As might be expected, the statistics show that the length of time these older systems remained intact was dependent on the implant length and diameter.

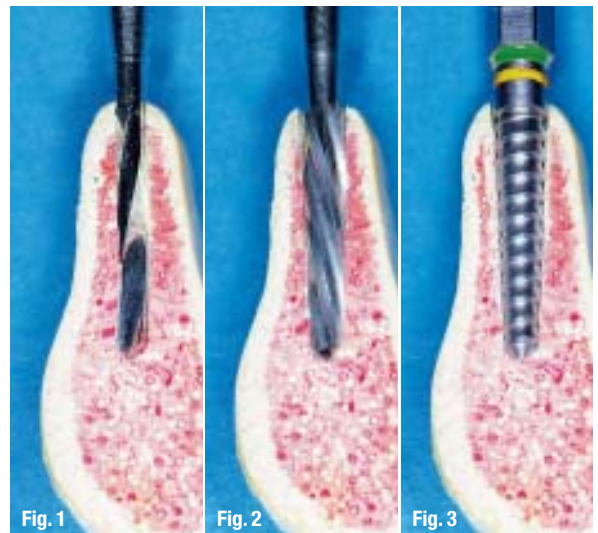


Fig. 1

Fig. 2

Fig. 3

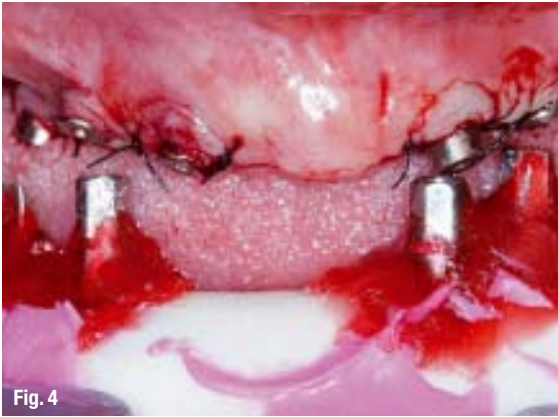

Fig. 4

The introduction of new technical methods has led to a trend over recent years towards stress-free, adhesive-bonded, electroplated telescopic dentures with secondary splinting which were, moreover, said to be more hygiene-friendly and capable of immediate loading, dependent on bone quality. However, after a five-year period, critics of this new and costly competition to traditional bar splinting consider their criticisms were justified. Examples of the areas of criticism include implant fracture or loss due to missed recalls, wear and tear of the electroplated primary parts because of insufficiently thick walls or incorrectly truncated cone angle, difficulty in recementing these high-precision anchoring elements and decreasing friction.

There are no long-term evidence-based studies available comparing these two divergent approaches to denture construction. This is partly because most authors, when considering the treatment of edentulous jaw sections, do not classify the resorption classes by case key for the upper jaw nor in accordance with at-wood for the lower jaw and are thus unable to make any comparisons of the starting positions (Fig. 13).

Legal considerations regarding explanations and liability have led manufacturers to recommend large implants. This in turn has led to practitioners making augmentative onlay grafts using CT and DVT before carrying out the implant in order to create a correspondingly large implant bed. For many of our older patients these new techniques are not yet available throughout the whole country. Apart from the increased time and expense these innovations involve, they are also, like X-rays, sometimes linked in the public's mind with fears of radiation and claustrophobia.

The mini-implants <math><3.3\text{ mm}</math> in diameter so popular with practitioners come up against the traditional prejudice of deficient tensile and compressive strength with rapid material fatigue. Improved titanium processing techniques have led in recent years to a substantial improvement in material properties (grades 4–5 instead of 2–3) which naturally improves the quality of smaller diameter implants with an outside connection, since their interior walls are not too thin.

The University of Applied Sciences at Koblenz (Prof Flach) and the Fraunhofer Institute Freiburg each carried

AD

Table 1

Position	Central incisor	Lateral incisor	Canine tooth
Upper jaw	204	179	273
Lower jaw	154	168	268

Implant type	Length [mm]	Surfaces in mm ² finely turned	Surfaces in mm ² sandblasted
S 3.25	8,5	109	158
	10	131	223
	11,5	153	260
	13	175	298
	15	204	347

Table 1 SEMADOS Implant surfaces.

Fig 6 Immediate integration and immediate loading of a non-precious metal bar is possible postoperatively.

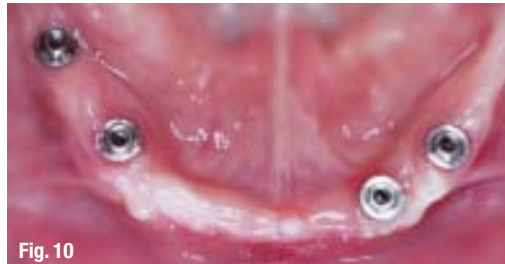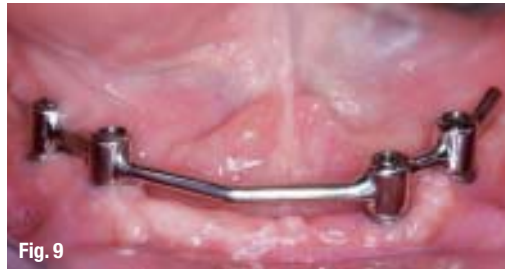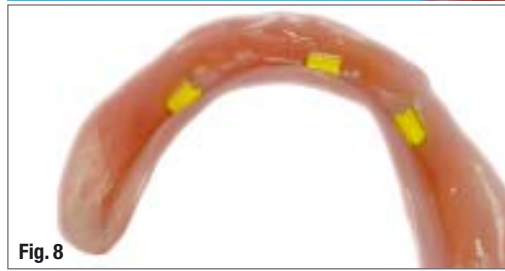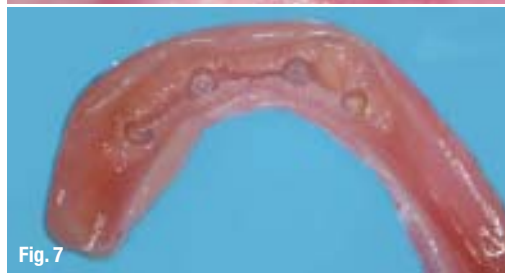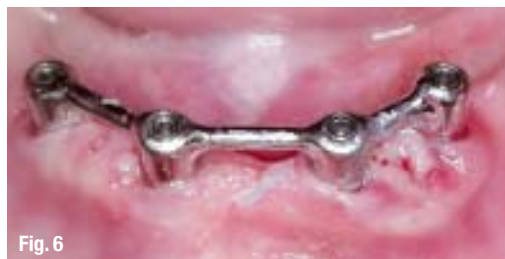Picture taken after removal of the stitches.

Fig. 7 Soft relined old lower jaw denture ready for immediate loading.

Fig 8 Reasonably priced fixing of the old denture with a bar rider including housing.

Fig 9 Bar frame bent to match the shape of the jaw.

Fig 10 Asymmetric positioning of the lower jaw implants three months after the operation.



out independent tests on Dr Dr R. Streckbein's design of narrow jaw implants based on high primary stability. Traditional treatment concepts lead to surgical milling of the knife-edged alveolar ridge. The loss in height causes problems at the soft tissue transition regions. The deterioration in the leverage forces of the dentures for implant anchoring puts an additional strain on all components and can lead to premature fracture and wear and tear in the case of delicate constructions. That is why the manufacturers of normal and large diameter implants recommend more expensive treatment concepts requiring the grafting of autogenous bone and non-autogenous material to build up horizontal and vertical deficits.

This procedure, which can be carried out on an outpatient or inpatient basis, is mainly performed only by oral and maxillofacial surgeons meeting the rigorous standards of the Robert Koch Institute. It is our older patients in particular who avoid further expensive and physically strenuous treatments. Streckbein and Knöfler see no statistically confirmed advantages in these procedures. Neukam and Esser point out risks involved in extensive osteoplasty.

Our task is to ensure that by using a QM system, which also includes bone management, patients with knife-edged alveolar ridges receive high-quality implant treatment. It should not be forgotten that quality in medicine is not absolute or transcendental. We must all agree on common criteria.

_Product-related criteria

The requirements for an implant system suitable for narrow jaws are:

- It should be tested by independent institutes in addition to testing for the CE mark.
- It should be minimally invasive with high primary stability.
- Abutment divergences up to 25 degrees can be compensated.
- Implant surface must at least match the tooth surface to be replaced as regards osseointegration.
- Surface of the natural anterior teeth (mm²) in accordance with Jepsen.
- Combination of bone spreading and bone condensing to displace the existing bone mass, ensuring osseointegration takes place and avoiding the danger of the loss of buccal osseous lamella associated with traditional methods.

_Price/performance-related criteria

Important considerations for patient and practitioner:

- Elimination of the expense of elaborate augmentation techniques.
- Number of screwed connections determines the risks and working life of a technical component, thus transmucosal connecting parts, etc should be avoided.

- Immediate restoration of the implants using a non-precious metal bar system with primary splinting, which is a more elegant and robust solution than traditional precious metals, thus permitting more thorough cleaning in the abutment-bar transition area. Moreover the system is significantly less susceptible to plaque.
- Use of a non-precious bar alloy when soldering the components.
- The use of laser technology eliminates the need for allergenic solders and enables the frame to be joined together without being placed under stress.
- Simple fitting of associated prefabricated female parts into existing full dentures, for example. Soft-loading with silicone-based relining after the operation and bar integration are possible.

_Process-related criteria

The main emphasis here, apart from a simple surgical procedure (Figs. 1–4), should be on a high-quality bar-borne denture (Figs. 14, 15) incorporating the advantages of a modern jointing technique (Fig. 5).

_What does this mean?

The patient does not have to undergo a second or third surgical procedure, and immediate loading (Figs. 6, 7) with predictable osseointegration (Fig. 12) can follow without any problems. The patient immediately experiences a vast improvement in their quality of life. An enhanced primary stability is achieved by success factors such as bone spreading and bone condensing by means of four screws in the lower jaw and six in the upper jaw (if there is a lack of anterior bone tissue, separate posterior bars are also possible, if necessary). (A recommendation by the leading scientific societies on billing these procedures can be downloaded from the website of the DGI [German Society of Implantology], www.dgi-ev.de, for example).

An innovative, minimally invasive concept changes the treatment spectrum at the narrow jaw-implant-denture interface, leading to increased acceptance by the patient (Figs. 8–11). For the implantologist mindful of competition, new prospects are opening up based on tried and tested procedures as well as opportunities and challenges for the future.

The literature list can be requested from the author.

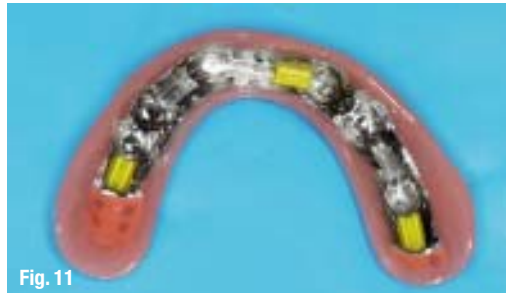

Fig. 11

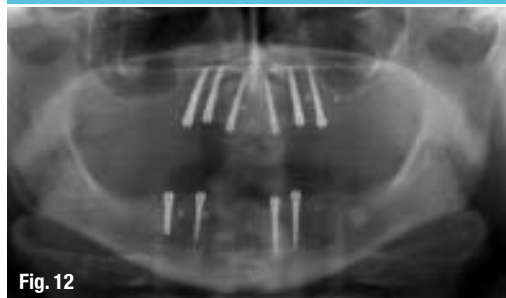

Fig. 12

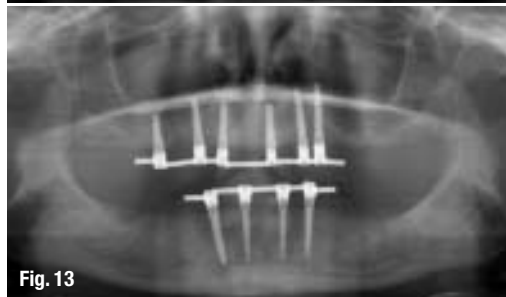


Fig. 13

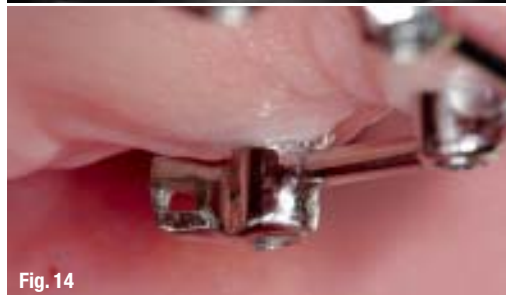

Fig. 14

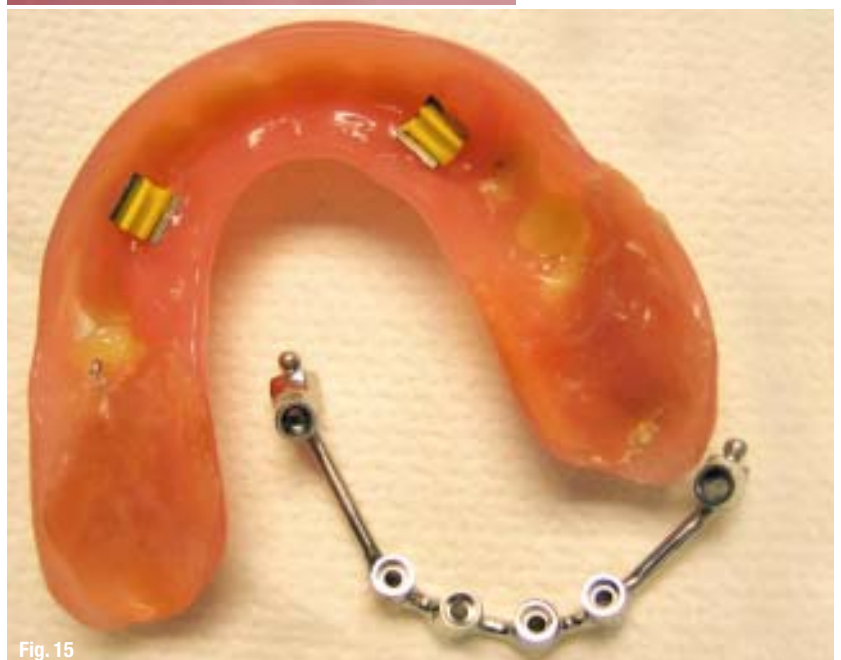

Fig. 15

Fig 11_Newly manufactured denture with a cast base and inserted female parts, which are easily interchangeable and, if desired, enable different withdrawal forces to be achieved.

Fig 12_Associated X-ray check after osseointegration (three months after operation).

Fig 13_X-ray check (three years after operation) of a narrow jaw case with the resorption classes, lower jaw front in accordance with Atwood 3–4 and upper jaw front in accordance with case key 2–3. As regards indication class III, upper jaw has six implants, lower jaw has four implants for removable dentures.

Fig 14_Swing lock that can also be fitted subsequently at any time into the existing non-precious metal construction to enhance wearing comfort.

Fig 15_There are some schools of thought relating to dental prosthetics that disapprove on grounds of excessive load of “free end bars” ending a long way distally. In this respect vario ball attachments, for example, have also proved their worth in reducing load.

_contact	implants
<p>Dr med dent Klaus Müller Tätigkeitsschwerpunkt Implantologie LZK Hessen Rudolfstr. 1 35764 Sinn, Germany E-mail: Dr.Klaus.Mueller.Sinn@t-online.de</p>	